



**PRESENTING CLINICAL SIGNS**

History: Enlarged heart on X-rays. Receiving Vetmedin.

**DATE**

12/26/22

**ECHOCARDIOGRAPHIC FINDINGS**

2D, M-mode, and Doppler study.

**PERFORMED BY:**

Sara Hansen

Left atrial size is normal. The mitral valve leaflets are mildly thickened, and a mild jet of mitral regurgitation is present. Left ventricular dimensions are normal. Left ventricular systolic function is hyperdynamic. The aorta and aortic valve are normal. Right atrial and right ventricular dimensions are normal. The tricuspid valve appears normal, though trace tricuspid regurgitation is present. The pulmonary artery and pulmonic valve are normal. No shunting lesions are visualized. No heartworms are visualized. No pericardial effusion or cardiac masses are seen.

**INTERPRETED BY**

Keith Blass, DVM,  
MS, DACVIM  
(Cardiology)

LA - 23.9 mm  
LVIDd - 24.4 mm  
LVIDs - 12.4 mm  
FS - 49%  
RA - 20.4 mm  
LVOT - 1.88 m/s  
RVOT - 1.41 m/s

**PATIENT**

Toby Eckert

**ASSESSMENT/RECOMMENDATIONS**

Degenerative mitral valve disease

**SPECIES**

Canine

This examination demonstrates mild regurgitation of blood across Toby's mitral valve resulting from degenerative valve disease. The hemodynamic effects of the regurgitation also appear to be mild, as Toby does not have secondary dilation of either of his left heart chambers. As such, Toby's mitral valve disease appears to be well-compensated, and his current risk for the development of clinical signs secondary to it, such as coughing, exercise intolerance, syncope, and labored breathing, appears to be low.

**BREED**

Chihuahua

Toby's current therapy with Vetmedin may be continued, if desired, though there is no definitive evidence proving a benefit of the medication at this stage of disease.

**SEX**

A recheck echocardiogram is recommended in 6 months. Repeat thoracic radiographs are recommended if Toby experiences respiratory clinical signs.

**MN**

**AGE**

7 y

**WEIGHT**

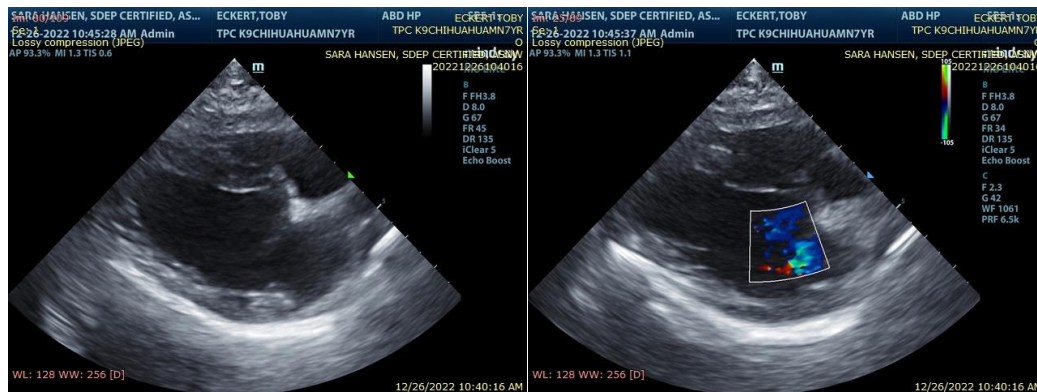
16.8 lb

**HOSPITAL NAME**

The Pet Clinic

**REFERRING VET**

Dr. Genova



The information and recommendations provided are based on the images presented by the referring veterinarian. No evaluation can be communicated regarding pathology that was not



visible in the image/video clips provided.

**DATE** Thank you for this referral. If the clinical or image interpretation does not parallel your findings or if I can be of any further assistance please contact me.

12/26/22

**PERFORMED BY:** Keith Blass, DVM, MS, DACVIM (Cardiology)  
KeithBlass@gmail.com  
631-804-5754

Sara Hansen

**INTERPRETED BY**

Keith Blass, DVM,  
MS, DACVIM  
(Cardiology)

**PATIENT**

Toby Eckert

**SPECIES**

Canine

**BREED**

Chihuahua

**SEX**

MN

**AGE**

7 y

**WEIGHT**

16.8 lb

**HOSPITAL NAME**

The Pet Clinic

**REFERRING VET**

Dr. Genova